

RESEARCH

Open Access



# Differential diagnosis of breast mucinous carcinoma with an oval shape from fibroadenoma based on ultrasonographic features

Hongli Wang<sup>1,2†</sup>, Yue Hu<sup>1,2†</sup>, Cui Tan<sup>1,3</sup>, Ran Gu<sup>1,2</sup>, Yudong Li<sup>1,2</sup>, Liang Jin<sup>1,2</sup>, Xiaofang Jiang<sup>1,2</sup>, Jingsi Mei<sup>1,2</sup>, Qiang Liu<sup>1,2\*</sup> and Chang Gong<sup>1,2\*</sup>

## Abstract

**Background** Approximately 50% of breast mucinous carcinomas (MCs) are oval and have the possibility of being misdiagnosed as fibroadenomas (FAs). We aimed to identify the key features that can help differentiate breast MC with an oval shape from FA on ultrasonography (US).

**Methods** Seventy-six MCs from 71 consecutive patients and 50 FAs with an oval shape from 50 consecutive patients were included in our study. All lesions pathologically diagnosed. According to the Breast Imaging Reporting and Data System (BI-RADS), first, the ultrasonographic features of the MCs and FAs were recorded and a final category was assessed. Then, the differences in ultrasonographic characteristics between category 4 A (low-risk group) and category 4B-5 (medium-high-risk group) MCs were identified. Finally, other ultrasonographic features of MC and FA both with an oval shape were compared to determine the key factors for differential diagnosis. The Mann-Whitney test,  $\chi^2$  test or Fisher's exact test was used to compare data between groups.

**Results** MCs with an oval shape (81.2%) and a circumscribed margin (25%) on US were more commonly assessed in the low-risk group (BI-RADS 4 A) than in the medium-high-risk group (BI-RADS 4B-5) (20%,  $p < 0.001$  and 0%,  $p = 0.001$ , respectively). Compared with those with FA, patients with MC were older, and tended to have masses with non-hypoechoic patterns, not circumscribed margins, and a posterior echo enhancement on US ( $p < 0.001$ ,  $p < 0.001$ , and  $p = 0.003$ , respectively).

<sup>†</sup>Hongli Wang and Yue Hu contributed equally to this work, they are co-first authors.

Chang Gong and Qiang Liu contributed equally to this work, they are co-correspondence authors.

\*Correspondence:

Qiang Liu  
victorlq@hotmail.com  
Chang Gong  
gchang@mail.sysu.edu.cn

Full list of author information is available at the end of the article



© The Author(s) 2024. **Open Access** This article is licensed under a Creative Commons Attribution 4.0 International License, which permits use, sharing, adaptation, distribution and reproduction in any medium or format, as long as you give appropriate credit to the original author(s) and the source, provide a link to the Creative Commons licence, and indicate if changes were made. The images or other third party material in this article are included in the article's Creative Commons licence, unless indicated otherwise in a credit line to the material. If material is not included in the article's Creative Commons licence and your intended use is not permitted by statutory regulation or exceeds the permitted use, you will need to obtain permission directly from the copyright holder. To view a copy of this licence, visit <http://creativecommons.org/licenses/by/4.0/>. The Creative Commons Public Domain Dedication waiver (<http://creativecommons.org/publicdomain/zero/1.0/>) applies to the data made available in this article, unless otherwise stated in a credit line to the data.

**Conclusion** The oval shape was the main reason for the underestimation of MCs. On US, an oval mass found in the breast of women of older age with non-hypoechoic patterns, not circumscribed margins, and a posterior echo enhancement was associated with an increased risk of being an MC, and should be subjected to active biopsy.

**Keywords** Breast, Ultrasonography, Mucinous carcinoma

## Background

Breast mucinous carcinoma (MC) is characterized by clusters of generally small and uniform cells floating in large amounts of extracellular mucin. It is a rare histological type with a prevalence of 1–7% among all breast carcinomas [1]. MC grows slowly, has a low rate of lymph nodal metastasis, and has a good prognosis [2, 3].

At present, ultrasonography (US) is one of the most widely available diagnostic options for women with breast mass [4]. The descriptions of ultrasonographic features of breast masses are mainly based on the Breast Imaging Reporting and Data System (BI-RADS) [5]. Morphological feature is an important factor in the differential diagnosis of benign and malignant masses [6, 7]. In general, an irregular shape is highly suggestive of malignancy, while an oval shape indicates benignity [6, 7]. However, as a slow-growing carcinoma, approximately 50% of MCs were oval shape [8]. Due to the relatively high frequency of MC with an oval shape, there is potential for misdiagnosing it as fibroadenoma (FA), which is the most common benign breast solid mass.

Bode et al. [9] reported that 92% of MCs could be classified as BI-RADS category 4 or above on US. However, the malignant ultrasonographic features of MCs are more subtle than those of typical breast carcinoma, and therefore some of them may be assessed as BI-RADS category 4 A. Compared with category 4B and above, the malignant likelihood of category 4 A lesions is low between 2% and 10%, which belong to low-risk. Furthermore, among category 4 A masses, the likelihood of malignancy is lower for those with an oval shape than for those with an irregular shape, even less than 2% [10]. Follow-up instead of biopsy is advised for the category 4 A masses with an oval shape, which may be MCs [10, 11]. Thus, MCs that were assessed as category 4 A may have a delayed diagnosis.

Therefore, first, this retrospective study explored the ultrasonographic features that lead to the assessment of MCs as BI-RADS category 4 A (low-risk group) by comparing them with BI-RADS category 4B and above MCs (medium-high-risk group). Second, the specific ultrasonographic features that can help differentiate MC with an oval shape from FA were identified.

## Methods

### Patients

The pathology database of our hospital was searched from January 2012 to January 2021 to identify surgically

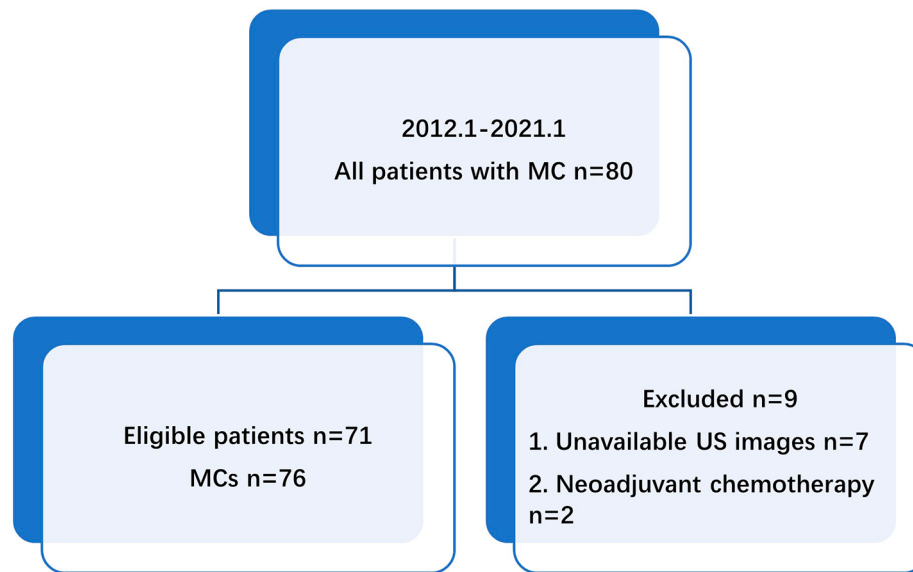
treated MC patients. Depending on the proportion of MC components, the MCs were separated into two pathologic types: pure mucinous carcinoma (PMC,  $\geq 90\%$  mucinous carcinoma) and mixed mucinous carcinoma (MMC,  $< 90\%$  mucinous carcinoma). The inclusion criteria for patients with MC were as follows: (1) surgical excision of the breast MCs; (2) breast US before biopsy in our hospital; (3) no history of breast cancer. The exclusion criteria were as follows: (1) unavailable US images; (2) neoadjuvant chemotherapy. Consequently, 76 MCs in 71 consecutive patients (two patients had three MCs each, and one patient had two MCs) (Fig. 1) were selected for retrospective analysis. Of these, 49 (64.5%) were PMCs, while 27 (35.5%) were MMCs.

In addition, the pathology database was searched for FA patients admitted between June 2019 and January 2021. The inclusion and exclusion criteria for patients with FA were the same as those for patients with MC, but the shape of the FA was limited to oval. If the patients had multiple FAs in the unilateral breast, the largest FA was included in our study. Finally, 50 FAs in 50 consecutive patients were selected for the research.

### Ultrasonography

Breast US examinations were performed with a high-resolution US unit (S2000, S1000 or ACUSON Oxana2; Siemens Medical Solutions, Erlangen, Germany). During the examination, the patients were in the supine position with their arms raised and hands placed behind their heads.

All US scans were performed and interpreted simultaneously by one dedicated breast radiologist with a minimum of 5 years of experience. The age of the patients [12] and the following features of MCs and FAs according to the fifth edition of the BI-RADS guidelines [5] were evaluated: maximum dimension (cm), shape (oval, irregular), orientation (parallel, not parallel), margin (circumscribed, not circumscribed), echo pattern (hypoechoic, isoechoic, heterogeneous and complex cystic and solid), posterior features (enhancement, no posterior features), calcifications in the mass (yes, no) and vascularity (absent, internal vascularity and vessels in rim). Because of the small number of cases in this study, isoechoic, heterogeneous and complex cystic and solid echo patterns were classified as non-hypoechoic pattern. Then, a final category was assessed. All MCs were assessed as category 4 A and above. Furthermore, MCs were divided into a low-risk group (category 4 A) and a medium-high-risk



**Fig. 1** Flow chart of the selection process for mucinous carcinoma (MC) patients

group (categories 4B-5). Consequently, 16 MCs were classified as the low-risk group and 60 were classified as the medium-high-risk group. Thirty-nine FAs were classified as category 4 A and 11 were classified as category 3. According to the BI-RADS guideline, category 3 lesions only require six months of follow-up, and no biopsy is needed. However, the 11 patients with category 3 FAs strongly requested and were granted biopsy.

### Statistical analysis

Age and maximum dimension were compared between groups using the Mann-Whitney test. The  $\chi^2$  test or Fisher's exact test was used to compare the ultrasonographic features of the low-risk and medium-high-risk groups of MCs as well as those of FAs versus MCs both with oval shapes on US. SPSS 20.0 (IBM, Chicago, IL, USA) was used for the statistical analyses. All *P* values were two-tailed, and  $P < 0.05$  was considered to indicate statistical significance.

## Results

### Patient and ultrasonographic features of MC

The median age of the 71 patients with MC was 47 years (range: 27–86 years). 76 MCs presented as masses on US. The median maximum dimension was 2.5 cm (range: 1.0–8.0 cm). The ultrasonographic features of the MCs are shown in Table 1. No correlations were found between the ultrasonographic features and pathologic types.

### Differences in ultrasonographic features of MC between the low-risk group and medium-high-risk group

According to the BI-RADS, the MCs were divided into a low-risk group (BI-RADS category 4 A) and a

medium-high-risk group (BI-RADS category 4B-5). The differences in the shape and margin between the two groups were statistically significant ( $p < 0.001$ ,  $p = 0.001$ , respectively) (Table 2), especially the former. A total of 81.2% MCs in the low-risk group but only 20.0% in the medium-high-risk group were oval. Moreover, all of the MCs in the medium-high-risk group had not circumscribed margins versus only 75% of MCs in the low-risk group.

### Comparison of ultrasonographic features between MC with an oval shape and FA with an oval shape

Next, the other ultrasonographic features of MC and FA both with an oval shape were compared. The differences in patient age, ultrasonographic margins, internal echo patterns, and posterior features between the two groups were statistically significant ( $p < 0.001$ ,  $p < 0.001$ ,  $p < 0.001$ ,  $p = 0.003$ , respectively) (Table 3). Compared to those with FAs (Fig. 2), the patients with MCs were older and more likely to have MCs with not circumscribed margins, non-hypoechoic patterns (including isoechoic, heterogeneous, complex cystic and solid echo), and with a posterior echo enhancement (Fig. 3).

## Discussion

Breast MC is rare in clinical practice, and a preoperative diagnosis is difficult to obtain due to the variability in ultrasonographic features and the overlap of its morphological features with those of benign tumours reported in the literature [8, 9, 13–17].

In our study, although most MCs showed malignant signs and were assessed as being medium-high-risk (BI-RADS 4B and above), 21.1% (16/76) MCs were assessed as low-risk (BI-RADS category 4 A), for which the

**Table 1** Ultrasonographic features of mucinous carcinomas

Features	MC	PMC	MMC	P value
Age	47 (41~61)	47 (42~57)	45 (39~65)	0.757
Maximum dimension	2.5 (1.7~3.2)	2.5 (1.7~3.4)	2.4 (1.8~3.0)	0.879
Shape				0.653
Oval	25 (32.9%)	17 (34.7%)	8 (29.6%)	
Irregular	51 (67.1%)	32 (65.3%)	19 (70.4%)	
Orientation				0.338
Parallel	65 (85.5%)	40 (81.6%)	25 (92.6%)	
Not parallel	11 (14.5%)	9 (18.4%)	2 (7.4%)	
Margin				0.323
Circumscribed	4 (5.3%)	4 (8.2%)	0 (0.0%)	
Not circumscribed	72 (94.7%)	45 (91.8%)	27 (100.0%)	
Echo				0.445
Hypoechoic	33 (43.4%)	21 (42.9%)	12 (44.5%)	
Isoechoic	25 (32.9%)	14 (28.5%)	11 (40.7%)	
Heterogeneous	16 (21.1%)	12 (24.5%)	4 (14.8%)	
Complex cystic and solid	2 (2.6%)	2 (4.1%)	0 (0.0%)	
Posterior features				0.838
No posterior features	27 (35.5%)	17 (34.7%)	10 (37.0%)	
Enhancement	49 (64.5%)	32 (65.3%)	17 (63.0%)	
Calcifications in the mass				0.822
No	67 (88.2%)	44 (89.8%)	23 (85.2%)	
Yes	9 (11.8%)	5 (10.2%)	4 (14.8%)	
Vascularity				0.161
Absent	15 (19.7%)	12 (24.5%)	3 (11.1%)	
Internal vascularity or vessels in rim	61 (80.3%)	37 (75.5%)	24 (88.9%)	

Abbreviations: MC: mucinous carcinoma; PMC: pure mucinous carcinoma; MMC: mixed mucinous carcinoma

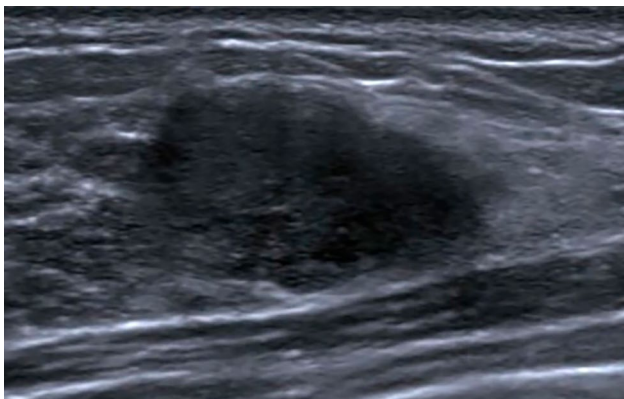
**Table 2** Differences in ultrasonographic features between the low-risk group and the medium-high-risk group of mucinous carcinomas

Feature	Low-risk group	medium-high risk group	P value
Age	48 (42~60)	46 (40~62)	0.610
Maximum dimension	2.1(1.5~2.8)	2.5 (1.8~3.5)	0.096
Shape			<0.001
Oval	13(81.2%)	12(20.0%)	
Irregular	3(18.8%)	48(80.0%)	
Orientation			1.000
Parallel	14(87.5%)	51(85.0%)	
Not parallel	2(12.5%)	9(15.0%)	
Margin			0.001
Circumscribed	4(25.0%)	0(0.0%)	
Not circumscribed	12(75.0%)	60(100.0%)	
Echo			0.976
Hypoechoic	7(43.8%)	26(43.3%)	
Non-hypoechoic	9(56.2%)	34(56.7%)	
Posterior features			0.115
No posterior features	3(18.8%)	24(40.0%)	
Enhancement	13(81.2%)	36(60.0%)	
Calcifications in the mass			0.225
No	16(100%)	51(85.0%)	
Yes	0(0%)	9(15.0%)	
Vascularity			0.098
Absent	6(37.5%)	9(15.0%)	
Internal vascularity and vessels in rim	10(62.5%)	51(85.0%)	

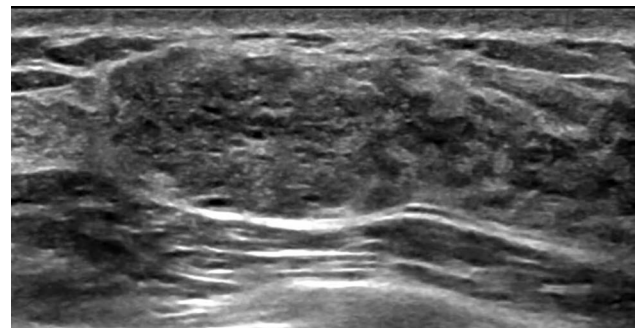
**Table 3** Comparison of other ultrasonographic features between MC with an oval shape and FA with oval shape

Features	MC	FA	P value
Age	47 (42~56)	30 (24~36)	< 0.001
Maximum dimension	2.3 (1.4~3.3)	2.1 (1.4~2.6)	0.306
Orientation			0.069
Parallel	22(88.0%)	49(98.0%)	
Not parallel	3(12.0%)	1(2.0%)	
Margin			< 0.001
Circumscribed	4(16.0%)	42(84.0%)	
Not circumscribed	21(84.0%)	8(16.0%)	
Echo			< 0.001
Hypoechoic	9(36.0%)	49(98.0%)	
Non-hypoechoic	16(64.0%)	1(2.0%)	
Posterior features			0.003
No posterior features	6(24.0%)	30(60.0%)	
Enhancement	19(76.0%)	20(40.0%)	
Calcifications in the mass			1.000
No	24(96.0%)	48(96.0%)	
Yes	1(4.0%)	2(4.0%)	
Vascularity			0.307
Absent	7(28.0%)	20(40.0%)	
Internal vascularity and vessels in rim	18(72.0%)	30(60.0%)	

Abbreviations: FA: fibroadenoma; MC: mucinous carcinoma



**Fig. 2** Fibroadenoma in a 34-year-old woman. An oval mass with a hypoechoic pattern, not circumscribed margins and no posterior features was found in the right breast. The mass was categorized as 4 A mainly because of the not circumscribed margin. Pathological diagnosis: fibroadenoma



**Fig. 3** Mucinous carcinoma in a 45-year-old woman. An oval mass with non-hypoechoic patterns, not circumscribed margins and a posterior echo enhancement was found in the right breast. The mass was categorized as BI-RADS 4 A mainly due to the not circumscribed margin. Pathological diagnosis: mucinous carcinoma

malignancy likelihood is exceptionally low. By comparing the ultrasonographic features of MCs in the low-risk and medium-high-risk groups, we confirmed that the majority (81.2%) of MCs in the low-risk group were oval shape. Lam et al. [8] reported that the ratio of oval shape masses on US was 40.6% for all MCs, 47.4% for PMCs and 30.8% for MMCs, while Kaoku et al. [15] reported that only 9.1% of PMCs were oval shape. In our research, an oval shape mass on US accounted for 32.9% (25/76) of all MCs, 34.7% of PMCs and 29.6% of MMCs. Apparently, the proportion of oval masses in PMCs was higher than in MMCs, but there was no significant difference between

the two in the current study and in previous studies. An oval shape is an ultrasonographic feature of benign breast masses, which may be suggested for follow-up instead of biopsy [10, 11, 18, 19]. On US, if the shape of MC is oval, its risk category may be underestimated. In addition to shape, there were also statistically significant differences in margin features between the low-risk group and the medium-high-risk group. However, although the percentage of MCs with a circumscribed margin in the low-risk group was higher than that in the medium-high-risk group, the majority (75%) of MCs in the low-risk group had not circumscribed margins, which is an ultrasonographic feature of malignancy [6, 7, 10, 11, 19]. Overall, oval shape was the main reason why MCs were

underestimated as low-risk which typically suggests a benign mass.

Fibroadenomas are the most common benign tumours of the breast [20]. Compared with patients with FA which is commonly found in young women (typically in 20 to 30 years old) [21], patients with MC in this study were older, with a median age 47 years, which is younger than the 51 to 71 years previously reported [22, 23].

Regarding ultrasonographic features, most FAs are oval or round, well circumscribed, hypoechoic with the long axis parallel to the skin surface and have normal or increased posterior echogenicity [24], which are almost consistent with our study findings. By comparing the other features of MC and FA both with an oval shape, we found that the margin features, internal echo patterns and posterior echo features were helpful for their differential diagnosis. Among internal echo pattern, margin and posterior features, the internal echo pattern is usually the first feature to attract the attention of ultrasound physicians. Hypoechoic is the most common type of echo in both typical benign and typical malignant masses [6, 7, 12, 19].

Compared with that of the FAs, the internal echo of most MCs was non-hypoechoic which included heterogeneous, isoechoic, or complex cystic and solid, which may be related to the complex tissue composition of MCs. MCs are composed of large amounts of extracellular mucin, stroma, and clusters of cancer cells. Kaoku et al [15] reported that the internal echo of MC varied with the proportions of the different components, particularly, the proportion of stroma tended to increase as the internal echogenicity increased.

Regarding the difference in the margin features of MCs and FAs, unlike the circumscribed margins of most FAs (84%), the margins of most MCs (84%) were not circumscribed in our study. Previous studies have reported that the percentage of MC with not circumscribed margins was between 23.5% and 95.0% [8, 9, 13, 14, 16]. The size of this range may be related to the different number of patients included in the studies. Compared with previous studies with fewer cases or only including PMCs, our study is more convincing, because it includes the largest number of patients and included two pathologic types, PMC and MMC. The not circumscribed margins of MC are related to the aggressive growth pattern of malignant masses [11, 19]. Furthermore, the posterior enhancement was another common ultrasonographic feature of MC. This is probably due to the transmission of the ultrasound beam through large amounts of extracellular mucin in MC [8].

This study had some limitations. First, our study only included commonly used ultrasonographic features. US elastography was not extensively used in our study, although it was added to the BI-RADS for US. Second,

the advantages of artificial intelligence in mucinous carcinoma diagnosis are becoming increasingly prominent [25, 26]. However, we had a small number of patients. We will collect more cases and attempt to use artificial intelligence to reduce the underestimation of mucinous carcinoma with an oval shape. Finally, this was a single-institution retrospective study. Multicentre studies with greater numbers of patients are needed to confirm our findings.

## Conclusion

In this study, MCs with an oval shape on US may be underestimated as low-risk. If an older woman presents with an oval breast mass with non-hypoechoic patterns, a posterior echo enhancement and not circumscribed margins, the possibility of MC should be considered, and active biopsy should be recommended.

## Abbreviations

BI-RADS	Breast Imaging Reporting and Data System
FA	Fibroadenoma
MC	Mucinous carcinoma
PMC	Pure mucinous carcinoma
MMC	Mixed mucinous carcinoma
US	Ultrasonography

## Acknowledgements

Not applicable.

## Author contributions

HL.W., Y.H., Q.L. and C.G. contributed to the conception and design of the work; C.T., R.G., Y.D. L., L.J., X.F.J. and J.S.M. contributed to the data acquisition; HL.W. and Y.H. contributed to the data analysis and interpretation; HL.W. and Y.H. drafted the work; HL.W. prepared the figures; Q.L. and C.G. revised it. All authors read and approved the final manuscript.

## Funding

This work is supported by the Natural Science Foundation of China (82371739、81872139、82072907、U1911204 and 51861125203); Project of the Beijing Xisike Clinical Oncology Research Foundation(Y-Roche2019/2-0078、Y-pierrefabre202102-0107); the Science and Technology Planning Project of Guangdong Province (2023B1212060013); the Fundamental Research Funds for the Central Universities, Sun Yat-sen University (2022005); High-tech, Major and Characteristic Technology Projects in Guangzhou Area (2023-2025) (2023P-ZD14); National Key R&D Program of China (2021YFC3001000).

## Data availability

Data can be obtained with appropriate reason by request to the corresponding author through email gchang@mail.sysu.edu.cn.

## Declarations

### Ethics approval and consent to participate

All procedures in this study were approved by the ethical review board committee of Sun Yat-Sen Memorial Hospital (SYSEC-KY-KS-2021-252) and in accordance with the 1964 Helsinki Declaration and its later amendments or comparable ethical standards. The informed consent was waived by the same ethics committee that approved the study (ethical review board committee of Sun Yat-Sen Memorial Hospital) due to the retrospective nature of the study.

### Consent for publication

Not applicable.

### Competing interests

The authors declare no competing interests.

**Author details**

<sup>1</sup>Guangdong Provincial Key Laboratory of Malignant Tumour Epigenetics and Gene Regulation, Sun Yat-Sen Memorial Hospital, Sun Yat-Sen University, Guangzhou 510120, China

<sup>2</sup>Breast Tumor Center, Sun Yat-Sen Memorial Hospital, Sun Yat-Sen University, Guangzhou 510120, China

<sup>3</sup>Department of Pathology, Sun Yat-Sen Memorial Hospital, Sun Yat-Sen University, Guangzhou 510120, China

Received: 25 June 2023 / Accepted: 16 January 2024

Published online: 03 February 2024

**References**

- Toikkanen S, Kujari H. Pure and mixed mucinous carcinomas of the breast: a clinicopathologic analysis of 61 cases with long-term follow-up. *Hum Pathol*. 1989;20:758–64.
- Bae SY, Choi MY, Cho DH, Lee JE, Nam SJ, Yang JH. Mucinous carcinoma of the breast in comparison with invasive ductal carcinoma: clinicopathologic characteristics and prognosis. *J Breast Cancer*. 2011;14:308–13.
- Cao AY, He M, Liu ZB, Di GH, Wu J, Lu JS, et al. Outcome of pure mucinous breast carcinoma compared to infiltrating ductal carcinoma: a population-based study from China. *Ann Surg Oncol*. 2012;19:3019–27.
- Berg WA. Current status of Supplemental Screening in dense breasts. *J Clin Oncol*. 2016;34:1840–3.
- Mendelson EB, Böhm-Vélez M, Berg WA, Whitman GJ, Feldman MI, Madjar H, et al. ACR BI-RADS ultrasound. In: *ACR BI-RADS Atlas, Breast Imaging Reporting and Data System* edn. Edited by D'Orsi CJ, Sickles EA, Mendelson EB, Morris EA. Reston: American College of Radiology; 2013: 1–173.
- Rahbar G, Sie AC, Hansen GC, Prince JS, Melany ML, Reynolds HE, et al. Benign versus malignant solid breast masses: US differentiation. *Radiology*. 1999;213:889–94.
- Hong AS, Rosen EL, Soo MS, Baker JA. BI-RADS for Sonography: positive and negative predictive values of sonographic features. *AJR Am J Roentgenol*. 2005;184:1260–5.
- Lam WW, Chu WC, Tse GM, Ma TK. Sonographic appearance of mucinous carcinoma of the breast. *AJR Am J Roentgenol*. 2004;182:1069–74.
- Bode MK, Rissanen T. Imaging findings and accuracy of core needle biopsy in mucinous carcinoma of the breast. *Acta Radiol*. 2011;52:128–33.
- Niu Z, Tian JW, Ran HT, Ren WD, Chang C, Yuan JJ, et al. Risk-predicted dual nomograms consisting of clinical and ultrasound factors for downgrading BI-RADS category 4a breast lesions - a multiple centre study. *J Cancer*. 2021;12:292–304.
- Yang Y, Hu Y, Shen S, Jiang X, Gu R, Wang H, et al. A new nomogram for predicting the malignant diagnosis of breast imaging reporting and Data System (BI-RADS) ultrasonography category 4A lesions in women with dense breast tissue in the diagnostic setting. *Quant Imaging Med Surg*. 2021;11:3005–17.
- Hu Y, Yang Y, Gu R, Jin L, Shen S, Liu F, et al. Does patient age affect the PPV3 of ACR BI-RADS Ultrasound categories 4 and 5 in the diagnostic setting? *Eur Radiol*. 2018;28:2492–8.
- Tan JZ-Y, Waugh J, Kumar B, Evans J. Mucinous carcinomas of the breast: imaging features and potential for misdiagnosis. *J Med Imaging Radiat Oncol*. 2013;57:25–31.
- Liu H, Tan H, Cheng Y, Zhang X, Gu Y, Peng W. Imaging findings in mucinous breast carcinoma and correlating factors. *Eur J Radiol*. 2011;80:706–12.
- Kaoku S, Konishi E, Fujimoto Y, Tohno E, Shiina T, Kondo K, et al. Sonographic and pathologic image analysis of pure mucinous carcinoma of the breast. *Ultrasound Med Biol*. 2013;39:1158–67.
- Memis A, Ozdemir N, Parildar M, Ustun EE, Erhan Y. Mucinous (colloid) breast cancer: mammographic and US features with histologic correlation. *Eur J Radiol*. 2000;35:39–43.
- Chopra S, Evans AJ, Pinder SE, Yeoman LJ, Ellis IO, Elston CW, et al. Pure mucinous breast cancer-mammographic and ultrasound findings. *Clin Radiol*. 1996;51:421–4.
- Bouzzghar G, Levenback BJ, Sultan LR, Venkatesh SS, Cwanger A, Conant EF, et al. Bayesian probability of malignancy with BI-RADS sonographic features. *J Ultrasound Med*. 2014;33:641–8.
- Elverici E, Barca AN, Aktas H, Ozsoy A, Zengin B, Cavusoglu M, et al. Nonpalpable BI-RADS 4 breast lesions: sonographic findings and pathology correlation. *Diagn Interv Radiol*. 2015;21:189–94.
- Stachs A, Stubert J, Reimer T, Hartmann S. Benign breast disease in women. *Dtsch Arztebl Int*. 2019;116:565–74.
- Cheema HS, Mehta R, Slanetz PJ. Imaging and management of fibro-epithelial breast lesions on percutaneous core needle biopsy. *Breast J*. 2020;26:1216–20.
- Barkley CR, Ligibel JA, Wong JS, Lipsitz S, Smith BL, Golshan M. Mucinous breast carcinoma: a large contemporary series. *Am J Surg*. 2008;196:549–51.
- Di Saverio S, Gutierrez J, Avisar E. A retrospective review with long term follow up of 11,400 cases of pure mucinous breast carcinoma. *Breast Cancer Res Treat*. 2008;111:541–7.
- Ciurea AI, Herta HA, Iacoban CG, Fetica B, Rogojan L, Ciortea CA. Fibroadenomas and breast carcinoma: a possible answer to a frequently asked question. A pictorial essay. *Med Ultrason*. 2018;20:385–91.
- Liang T, Shen J, Zhang S, Cong S, Liu J, Pei S, et al. Using Ultrasound-based Multilayer Perceptron to differentiate early breast Mucinous Cancer and its subtypes from Fibroadenoma. *Front Oncol*. 2021;11:724656.
- Wang H, Zha H, Du Y, Li C, Zhang J, Ye X. An integrated radiomics nomogram based on conventional ultrasound improves discriminability between fibroadenoma and pure mucinous carcinoma in breast. *Front Oncol*. 2023;13:1170729.

**Publisher's Note**

Springer Nature remains neutral with regard to jurisdictional claims in published maps and institutional affiliations.